XXXIII. *Continuation of the Case of* James Jones. *By* Richard Browne Cheston, *Surgeon to the* Gloucester *Infirmary. Communicated in a Letter to Mr.* Henry Watson, *Surgeon to the* Westminster *Hospital.* *(See p.* 323.)

Read November 16, 1780.

DEAR SIR,

I HAVE it at last in my power to inform you of the state the bones of the *pelvis* appeared in after a *maceration* of five months: for though by very seldom changing the water, and keeping the vessel containing it rather in a warm place, I suffered the highest putrefaction to come on, it took up that space of time before the soft parts were entirely destroyed.

In my account of the state in which I found the *thoracic duct* of the same subject, I mentioned my suspicions (from the only examination I then had it in my power to make) that a considerable part of the substance of the *os innominatum* was destroyed or absorbed; but *maceration* has cleared up this circumstance, and shewn, that the depth the probe entered, and the gritty resistance

The Royal Society is collaborating with JSTOR to digitize, preserve, and extend access to *Philosophical Transactions of the Royal Society of London.* www.jstor.org

reſiſtance I felt in the body of the tumor, was not from its paſſing through a carious or diſeaſed part, as there was reaſon then to ſuppoſe, but from the quantity of oſſeous matter depoſited on the outward ſide of the *os innominatum*; and that the part ſo loaded with it externally, and as it afterwards proved to be *internally*, was apparently in a ſound ſtate.

It is difficult to fix upon the preciſe part where the tumor occupying the right moiety of the *pelvis*, and containing the boney matter, originated. There is, however, every reaſon to ſuppoſe it began low down in the *pelvis* under the *peritoneum*, as the ſurface of the tumor was evidently covered with that membrane; and from every circumſtance in the appearance of the tumor, as well as a careful examination of it, during the progreſs of its diſſolution, it is probable, that paſſing out of the *pelvis* anteriorly through the *foramen ovale*, as well as laterally under the *iſchium*, and riſing upwards over the ſpine of the *ilium*, it formed a complete communication from within outwardly, ſo as to envelope the whole of the right *os innominatum* entirely.

As the ſoft parts of the tumor decayed in maceration, great quantities of boney matter in irregular forms and of different ſizes were found in the water at the bottom of the pan; and as no force, nor even

motion, had been uſed which could have ſeparated this matter from what remained adherent to the bone, it is highly probable it was ever depoſited in, and diſperſed through, the tumor in a detached ſtate.

The tumor, externally, bore the uſual appearances of a diſeaſed or enlarged gland; but, by degrees) as I had opportunities to obſerve upon changing the water) the whole appearance was changed, and the boney matter, as the maceration proceeded, ſeemed ſurrounded by a hard, white, and rather tranſparent ſubſtance, not much unlike ſuet, in which ſtate it principally reſiſted the diſſolvent power of the water.

When the bone in general ſeemed ſufficiently cleanſed for drying, I found in one part ſome remains of this ſuety ſubſtance; but as I was unwilling to continue the whole in water any longer for the ſake of this ſmall portion, and thought beſides that in its drying I might get ſome inſight into its nature, I expoſed it to the open air, and was ſurprized to find that in the courſe of three days it was intirely diſſipated, ſcarcely a trace of it remaining, unleſs that, in the particular portion alluded to, the boney matter was of a more duſky colour than elſewhere.

I had now the ſatisfaction to find the attention and care beſtowed upon the bones during the maceration amply repaid by the ſingularities which they preſented.

The left *os innominatum* was perfectly free from any unnatural appearance in every part, even to its junction at the *ſymphyſis* of the *pubis*; but there the line was drawn, and diſeaſe immediately began to ſhew itſelf through the whole of the right *os innominatum*, and to advance as it were from a ſuperficial ulceration to excreſcences in the greateſt quantity.

It is remarkable, that the cartilage connecting the *oſſa pubis* ſhould be ſo complete a boundary to the diſeaſe; for though the external *lamella* was in all that part of the *os pubis* and *iſchium* (particularly at the *ramus* of the latter) which united forms the *foramen ovale*, not the leaſt deficiency is to be obſerved in the left *os pubis*. So intereſting to the knowledge of the nature of this diſeaſe is it to obſerve that the extent of the tumor, which terminated exactly at this part, ſhould likewiſe as exactly have limited its effects or conſequences.

So far then as the external *lamella* of the *os pubis* and *iſchium* was deficient, ſo far theſe bones preſented that roughneſs and irregular loſs of ſubſtances which is commonly denominated ulceration or ſuperficial *caries*. The bottom of the *acetabulum* had likewiſe ſuffered in a ſimilar manner: but over the whole of the *ilium*, both externally and internally, the *lamellæ* ſeemed very little injured, though covered by vaſt quantities of boney

matter branching out into various forms of different ſizes, which a minute examination and careful attempt to ſeparate aſcertained to be mere, though firm, adheſions to the ſurface of the bone, and adventitious to the part on which they were found.

I am, &c.

Glouceſter,
November 1, 1780.

EXPLANATION OF THE DRAWINGS.

N° I. A front view of the *pelvis*.

It may only be neceſſary to obſerve here, as the drawing is ſo expreſſive of the original, that the centre of the external part of the *ilium* is not covered with boney matter in ſuch quantities, or of ſuch a ſize, as there is around and over the poſterior part of the *criſta* or ſpine, and where this bone forms a junction with the *os ſacrum*; yet there is not the ſpace of a ſix pence which has not more or leſs of it on it.

The *os ſacrum*, though apparently found, is likewiſe ſprinkled with it in ſeveral places.

N.° 1.
SICKELTS DEL.
BASIRE SC.

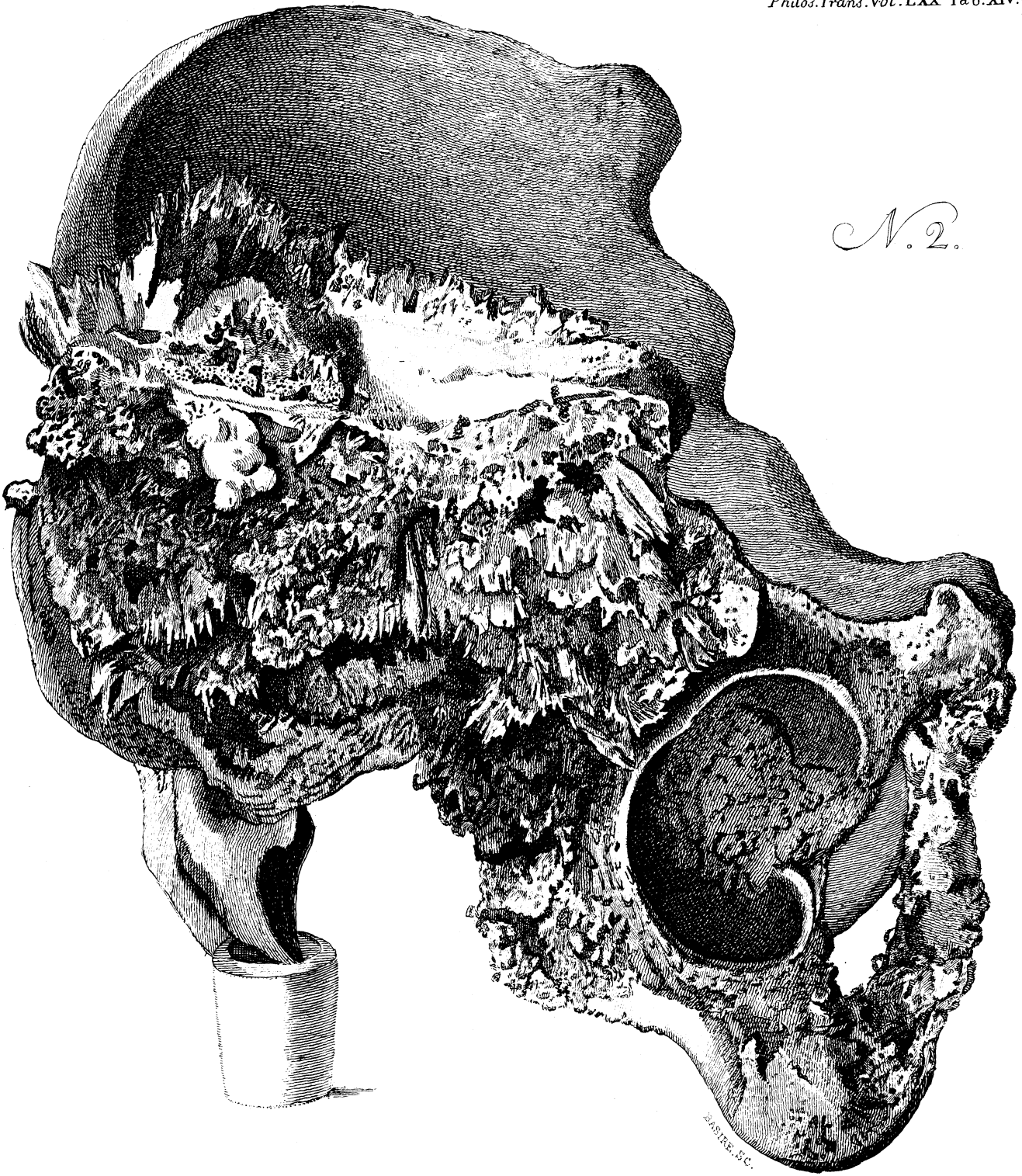
N. 2.

N° II. A ſide view of the *pelvis*, ſhewing,

1. In the *acetabulum* a ſlight eroſion.

2. The boney matter in different forms and ſizes on the outward ſide of the *ilium*.

3. The *os ſacrum* ſlightly expreſſed, reſting on a cork.

4. The *criſta* of the *ilium* at the poſterior part thickly covered with boney matter; at the anterior, free from it.

I have made no references in the drawings, as the above remarks will be ſufficiently obvious.

N.° 1.